

Update on placentitis in mares: diagnosis and treatment

Igor Canisso DVM, MSc, PhD, Dipl. ACT, Dipl. ECAR (Equine Reproduction)
Assistant Professor of Equine Theriogenology
Department of Veterinary Clinical Medicine
College of Veterinary Medicine
University of Illinois Urbana-Champaign
Urbana IL 61802, USA

Introduction

- Placentitis is estimated to affect 3 to 5% of pregnancies in Thoroughbred mares
- Late-term pregnancy wastage generates several million dollars of losses to the lost expense of producing a pregnancy (e.g. stud fees, semen transport, feed, vaccinations, veterinary services, etc.)
- Late term pregnancy loss may cause emotional stress to the owner with high expectations for the foal from a particular mating
- Placental pathology/insufficiency may be responsible for >60% of pregnancy losses due to abortion, stillbirth and neonatal death (up to 24 h post-delivery)

Etiology and Epidemiology

- Bacteria are responsible for the large majority of cases and fungi for the minority, mixed bacterial and fungal infections have been reported in ascending, however, less commonly.
- Common bacterial agents: *Streptococcus equi* subspecies *zooeidemicus*, *Escherichia coli*, *Streptococcus equisimilis*, *Klebsiella pneumoniae*, *Pseudomonas aeruginosa*, *Leptospira* sp, *Crossiella equi* and *Amycolatopsis* species (*Amycolatopsis kentuckyensis*, *Amycolatopsis lexingtonensis* and *Amycolatopsis pretoriensis*).
- Fungi associated with placentitis: *Aspergillus* spp and *Candida albicans*.
- Anecdotally it appears that some cases start with bacterial placentitis and then fungal secondary infections follow the primary bacterial infection
- Leptospiral infections can be variable cause of abortion across the country
- In North America, the serovar Pomona type *Kennewicki* is the most important type associated with Leptospiral abortions in mares; though, in other parts of the world, the serovars Bratislava, Grippotyphosa, Copenhageni, Autumnalis, Hebdomadis, Arborea and Icterohaemorrhagiae are more commonly associated with abortion in mares.
- Environmental conditions (i.e. precipitation and flooding) and wild animals (e.g. raccoons, white tailed deer, striped skunks, opossums, and foxes), are thought to be important in the dissemination of the bacteria from wildlife to horses, which are considered incidental hosts.

Pathogenesis

- Four morphologic types of placentitis: ascending, focal mucoid (nocardioform), diffuse (hematogenous), and multifocal
- **Ascending placentitis:** most frequent type of placentitis- commonly associated with β hemolytic streptococci and coliforms
- **Nocardioform placentitis:** commonly associated with Gram-positive branching bacilli, *Crossiella equi* and *Amycolatopsis* species. Recently, two new species of *Streptomyces* (*Streptomyces atriruber* and *Streptomyces silaceus*) have been isolated in nocardioform placentitis cases. It appears that *Crossiella equi* infections may be more likely to result in abortion, whereas infections with other type actinomycetes tend to result in live but premature foals.
- **Multifocal placentitis:** has a rare distribution pattern -is sporadically seen in isolated cases in association with fungi or bacteria.
- **Diffuse placentitis:** is diagnosed in isolated cases in association with bacteria or fungi, or during outbreaks in association with Leptospirosis
- Infectious agents associated with **ascending placentitis** appear to enter the uterus via the vagina/cervix and then colonize the caudal pole of the chorioallantois.
- Clinical signs: premature udder development (\pm streaming of pre-foaling mammary gland secretions), and vulvar discharge
- Normal mammary gland development begins approximately 4 wks (2 to 6 wks) prior to foaling, with more pronounced development in the wk immediately preceding parturition.

- Premature mammary gland development is a non-specific sign of pending late-term pregnancy loss, which can be associated with a variety of other pathological conditions (twin pregnancy, umbilical cord torsion, and idiopathic/unspecific imminent abortion).
- Enlargement of the mammary gland may be observed in mares suffering with hydrops, pre-pubic tendon rupture (which mammary gland may be filled with serosanguinous or bloody material and may be cranially displaced), and normal pre-foaling ventral edema.
- In mares suffering with placentitis, premature mammary development might not be present until the placental lesions are well advanced (e.g. placental separation).
- Vulvar discharge is highly variable as the discharge can be smeared by and accumulate under the tail and easily be missed, without close and frequent monitoring.
- If early treatment is not instituted the lesions will progress, and the infectious agent(s) may gain access to the fetus.
- Anecdotally, it has long been suggested that infectious agents gain access through the fetus by infecting the allantoic and amniotic fluids, however, our recent work suggest that contamination of the fetal fluids are not a primary route of fetal infection, but rather the infection of blood vessels.
- Infection of the chorioallantois is associated with prostaglandin production and increased expression of pro-inflammatory cytokines (e.g. IL-6 and IL-8).
- Lesions in mares with ascending placentitis are not restricted to the chorioallantois and can be associated with both funisitis (i.e. inflammation of the umbilical cord) and amnionitis.
- Ultimately, prostaglandin release might lead to abortion or delivery of a premature foal.
- Chronic placentitis leads to placental insufficiency, which may result in intrauterine fetal growth retardation and delivery of nonviable or weak foals.
- Foals born alive from mares with placentitis may be septic and may demand intensive veterinary critical care.
- Intuitively, early diagnosis and appropriate treatment are likely to improve the odds of delivering a live and useful foal.
- Placentitis accelerates the hypothalamic-pituitary adrenal axis (HPA) maturation which is in contrast to premature labor associated with other causes
- Mares with placentitis may deliver live and viable foals by 310 days of gestation, while dead or unviable foals are more commonly delivered from pregnancies of comparable gestational age of mares without placentitis that are interrupted early.
- The mechanisms associated with survival of preterm foals from mares with placentitis are unclear, but it has been suggested that it is related to a premature rise in fetal ACTH and cortisol. Different from other species, final maturation of the equine fetal HPA occurs in the few days immediately preceding normal parturition and continues during the first several weeks after birth. Foals born prematurely have lower cortisol concentrations (<3µg/dL) within 2 hours post-delivery compared to normal full-term foals (12-14 µg/dl).
- In addition, premature foals showed remarkably higher ACTH concentrations in comparison to normal full-term foals, 650 pg/mL vs 300 pg/mL 30 minutes post-delivery.
- In mares with placentitis, treatment strategies to prevent premature delivery should be instituted, prolonging fetal time *in utero* to allow greater fetal maturation and improve the possibility of neonatal survival. Conflicting opinions exist as to whether or not mares suffering with placentitis close to 340 days should have parturition induced to minimize the fetal exposure to bacteria and toxins and inflammatory products; however, longer fetal residence in the uterus is more likely to support fetal maturation.
- Nocardioform placentitis was first recognized ~20 yrs ago in Kentucky; however, little is known about the pathogenesis of this disease. Lesions in this type of placentitis are located in the uterine body and base of the uterine horns with no association with the cervical star.
- As a consequence, vulvar discharge is not commonly observed in the mare with nocardioform placentitis unless the mare is about to abort. .
- Because nocardioform infection is constrained to the chorioallantois (i.e. amnion, umbilical cord and fetus are not affected), chorionitis and induced placental insufficiency (i.e. in-utero growth restriction) are thought to be responsible for the fetal maturation.
- Little is known about the pathogenesis of diffuse or multifocal placentitis. It is suggested that the microorganisms reach the uterus hematogenously; however, there has been speculation that multifocal placentitis is the result of a dormant chronic infection of the uterus that became active later in pregnancy.
- In multifocal placentitis, lesions can be confined to the chorion and may also be present on the allantoic surface.

- Leptospira, the most important cause of hematogenous (or diffuse) placentitis, is believed to gain access to the uterus through the systemic circulation. Leptospiral lesions include amnionitis, funisitis and acute inflammatory changes in the chorioallantois.
- Interestingly, leptospiral abortions are associated with high immunoglobulin titers in maternal and fetal plasma, different than other types of placentitis.
- Leptospira is believed to cause abortion directly by infection of the fetoplacental unit, but it appears that systemic inflammation in association with hyperthermia and prostaglandin production may contribute to the pregnancy loss.

Diagnosis

- Based on ultrasonography and clinical signs (i.e. premature lactation and/or vulvar discharge).
- Transrectal ultrasonography of the caudal placental pole is commonly used to diagnose ascending placentitis.
- While performing this technique, the operator should make a midline alignment of the transducer with the cervix and ventral aspect of the caudal pole, to assure that a branch of uterine artery/cranial vaginal artery is imaged. Three measurements are usually taken of the combined thickness of uterus and placenta (CTUP) and the values can be compared to reported normal ranges.
- Increased CTUP associated with clinical signs and areas of placental separation are suggestive of ascending placentitis.
- Measures of CTUP outside the normal published ranges does not necessarily indicate placentitis, but rather normal variation, and at times artefacts associated with improper use of the technique.
- Transabdominal ultrasonographic examination of the fetus and placenta has been used as a tool to assess fetal and placental health. This approach is a particularly useful clinical tool in suspected nocardioform placentitis. However, since a very limited area of the uterus is accurately visualized by transabdominal ultrasonographic examination, the lack of apparent lesions in the chorioallantois does not exclude the possibility of disease.
- Areas of placental separation with hyperechoic exudate between the chorioallantois and the uterus are suggestive of nocardioform placentitis.
- Presumptive diagnosis of nocardioform placentitis can be challenging, especially if only a small area is affected.
- Fetal heart rate monitoring and ultrasonographic character of the fetal fluids can also be evaluated by transrectal and transabdominal ultrasonography.
- Reduced or increased fetal heart rates (normal heart rate ~80 beats per minute during late pregnancy) are associated with poor pregnancy outcome.
- Increased echogenicity of the fetal fluids are associated with imminent abortion.
- It is worth noting that the echogenicity of the amniotic fluid increases with gestational age, probably related to the vernix being released by the fetus. However, fetal stress (e.g. colic surgery, fetal hypoxia by different reasons) may result in fetal diarrhea, and echogenicity of the amniotic fluid may increase remarkably as consequence of solid particles floating in the amniotic fluid.
- The normal amnion appears as a thin membrane surrounding the fetus; amnionitis can be observed by ultrasonography as a thickened and irregular amniotic membrane.
- Cytology and culture swabs obtained from the external cervical os in pregnant mares can be beneficial in cases of ascending placentitis, when the cervix is open and discharge is present.
- Samples for culture and cytology can be collected with the use of a double-guarded cytobrush/swab via vaginoscopy or manually with a sterile sleeve. The presence of neutrophils, bacteria, and/or fungal hyphae will aid the presumptive diagnosis and give some clues about the type infection (i.e. Gram positive/negative and shape, or presence of hyphae) while waiting for further diagnostic tests.
- Definitive diagnosis of placentitis is attained by pathologic and microbiologic examination of the placenta.
- Ordinarily, the placenta should be laid out in an “F” or “Y” shape, thereafter the chorionic surface of the chorioallantois is examined and sampled.
- Macroscopic examination of the placenta allows determination of the affected areas, classification of the lesions and sampling for further examinations (i.e. histopathology and microbiologic evaluations). Placenta should be inverted to expose the allantoic surface of the chorioallantois, similarly the placenta should be laid out in an “F” shape, the amnion and umbilical cord should be spread out, examined and sampled for pathologic examination.
- Affected areas, normal tissues, and areas of transition between the normal and affected tissues should be sampled from the chorioallantois, amnion and umbilical cord.

- As part of the diagnostic testing for abortion cases, swabs should be collected from affected placental tissues and then used for bacterial culture and PCR testing for abortigenic infectious agents (e.g. *Leptospira*, equine herpesvirus type 1, equine arteritis virus).
- Fetal tissues (e.g. brain, liver, spleen, kidney, heart and lungs) and fetal body fluids (e.g. heart blood, thoracic and abdominal fluids) can be used for diagnostic testing.
- Fragments of placenta and fetal tissues can be collected, pooled, and be used for culture and PCR testing. A combination of different diagnostic methods will improve the diagnostic accuracy.
- Lesions detected upon histopathologic examination of the placenta vary with the infectious agent involved and chronicity of the infection.
- Acute bacterial placentitis is characterized by neutrophilic infiltration of the inter-villous space and/or necrosis of the chorionic villae.
- Chronic placentitis is associated with necrosis of the chorionic villi, presence of eosinophilic amorphous material in the chorion, and/or infiltration of mononuclear cells in the intervillous spaces.
- Other lesions reported in association with chronic placentitis include chorioangiomas, hyperplasia with or without squamous metaplasia of the chorionic epithelium, and adenomatous hyperplasia of the allantois.
- Leptospiral placentitis is characterized by edema, placental hemorrhage, brown mucoid material, green discoloration, cystic adenomatous hyperplasia of the allantois, vasculitis, amnionitis and funisitis as well as by the presence of spirochetes.
- Severe fetal lesions are also a remarkable feature of leptospiral abortion; the aborted fetus may be emaciated and icteric, present generalized edema and fluid accumulation and severe degenerative inflammatory lesions of lungs, liver, kidneys.
- In nocardioform placentitis, the macroscopic lesions are focal-extensive at the base of the uterine horn(s) and cranial uterine body on the chorionic surface of the chorioallantois, without involvement of the cervical star.
- A brown tenacious, mucoid material is found overlying white granular punctuate lesions. Histopathologic lesions are chronic-active; severely affected villi are often necrotic and coated with an extensive layer of eosinophilic amorphous material mixed with neutrophils and colonies of long filamentous branching bacteria.
- In less severely affected areas the same type of exudate is present in the crypts, and mononuclear cells are present in the villous stroma and chorionic stroma. Endometritis is a common finding in mares presenting with ascending placentitis.
- Adenomatous hyperplasia with or without squamous metaplasia of the chorionic epithelium is frequently observed in nocardioform and chronic placentitis.
- Bacterial cultures of the affected areas are routinely used as part of the necropsy diagnostic testing in pregnancy loss cases (i.e. abortion cases, premature delivery and suspicious placentitis cases).
- Methods and procedures for culture of nocardioform actinomycetes have been recently improved.
- Analyses by PCR for actinomycetes (i.e. *Crossiella equi* and *Amycolatopsis* ssp) has been incorporated as a routine test for the diagnosis of nocardioform placentitis in central Kentucky.
- Advantage of PCR in comparison to other diagnostic tools includes a rapid turnaround time; however, the specificity and sensitivity for PCR detection have not been reported. At present, as for other abortigenic diseases, the combination of the different diagnostic methods is highly recommended to maximize diagnostic accuracy.
- Fungal placentitis is commonly associated with chronic extensive placentitis at the cervical star. Similar to chronic bacterial placentitis, some fungi induce multifocal granulomatous placentitis.
- Adenomatous hyperplasia of the allantoic epithelium, with or without squamous metaplasia, can be commonly observed in chronic placentitis (e.g. fungal placentitis, *E. coli* and nocardioform placentitis).

Treatment

- Bacterial infection of the mare uterus in the middle of gestation may result in abortions with no lesions in the fetal membranes and minimal to no outward clinical signs (e.g. vulvar discharge, premature mammary gland development) - **treatment is often not an option to prevent this type of abortion.**
- Bacterial infections of the uterus late in pregnancy tend to be associated with acute/chronic placentitis - These mares will usually show the clinical signs as described above, thus if a diagnosis is made early enough, treatment can be applied and pregnancies can be potentially rescued.
- Treatment for placentitis should be aimed to prolong maintenance of a viable fetus in utero to allow time for fetal development and maturation. To achieve this goal, therapy should:
 - 1) Control bacterial infection of placenta and fetus,
 - 2) Maintain the myometrial quiescence

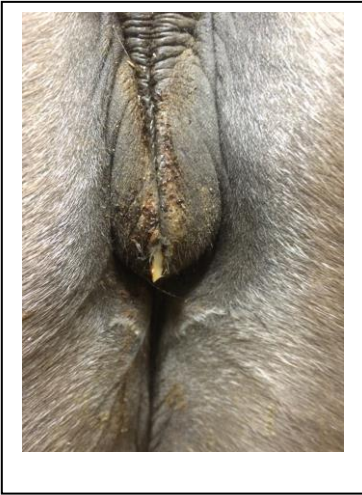
3) Block the production of pro-inflammatory cytokines.

- Treatment for placentitis: based on a combination of antibiotics, anti-inflammatories, and progestins.
- Anti-inflammatories are used to inhibit prostaglandin production and expression of pro-inflammatory cytokines.
- Progestin therapy for mares with placentitis: block myometrial contractions.
- Antibiotics are included as part of the therapy for the bacterial infection of the fetal membranes and to treat and/or prevent bacteria reaching the fetus.
- Few antimicrobials (sulfa-trimethoprim, penicillin and gentamicin) have been shown to cross the placental barrier and to achieve effective minimal inhibitory concentrations (MICs) in the fetal fluids and fetus against common bacteria causing placentitis.
- *Ceftiofur crystalline free acid, a drug that has effective in vitro antimicrobial activity against many bacteria causing placentitis was recently tested. Unfortunately, administration of ceftiofur crystalline free acid to pony mares did not result in concentrations of desfuroylceftiofur acetamide (i.e. the active metabolite) needed to effectively treat bacterial placentitis, and it did not improve survival of foals born from mares with experimentally induced ascending placentitis. These findings discourage the use of this antibiotic to treat placentitis in mares.*
- Controversy exists regarding the duration of antimicrobial therapy once a diagnosis of placentitis is made. Anecdotally, short antimicrobial treatment (i.e. 10-15 days) has been advocated to be an effective and a thoughtful approach to treat placentitis as well as an approach to avoid bacterial resistance associated with prolonged antimicrobial therapy. However, evidence-based findings in mares with experimentally induced placentitis do not support the claim for effectiveness of short-term antimicrobial therapy. In fact, mares with experimentally induced ascending placentitis did not carry foals to term when treatment was discontinued after 2 weeks; however, an apparent increase in survival rates was observed when mares were kept on antimicrobials for a prolonged period of time. Another interesting finding about antimicrobial therapy from the same group demonstrated that mares kept on a prolonged treatment with antibiotics, present positive endometrial bacterial culture within 6 hours post abortion or delivery of a viable foal. These findings suggest that antimicrobials administered to mares with experimentally induced placentitis may suppress bacterial growth, but do not achieve complete bacterial elimination.
- Empirically, estrogen supplementation has been advocated to treat mares with placentitis. As aforementioned, this author reported that mares with placentitis that subsequently aborted had remarkably lower “total estrogen” concentrations than mares of the same gestational age that maintained pregnancy. As estrogens are produced in high concentrations during the second and third trimesters of pregnancy, it is unlikely that estrogen supplementation will be able to restore normal estrogen concentrations. For example, it required continuous intravenous infusion of 126-231 mg of estrone sulfate per hour to achieve peripheral pregnancy levels of estrone sulfate. Therefore, to date, estrogen therapy has not been critically assessed by controlled studies or prospectively assigned field studies.
- Other drugs that have been added to the treatment of equine placentitis include acetylsalicylic acid, pentoxifylline, and dexamethasone. Acetylsalicylic acid has been given to mares with placentitis under the impression that this drug would improve the blood flow to the mare’s uterus; however, there is no evidence-basis in the literature to support this practice. In human medicine, low dose of acetylsalicylic acid has been shown to reduce the risks of preeclampsia in women.
- Pentoxifylline has been included with the idea that this drug possesses antiinflammatory and rheolytic properties which might improve the oxygenation of the pregnant uterus. Pentoxifylline was with experimentally induced placentitis - **It is unclear whether this drug has any beneficial effect on the found to be present in the fetal fluids of pregnant mares treated**
- Dexamethasone has been included in the treatment of placentitis; however, it is uncertain whether administering this drug improves pregnancy outcome in mares with placentitis. At best, very limited to no evidence-basis exists to support the practice to include these drugs (i.e. acetylsalicylic acid, pentoxifylline, and dexamethasone) in the treatment of placentitis.
- Tocolytic (e.g. clenbuterol and isoxsuprine) have also been used in practice as part of the treatment of mares with placentitis; however, there is no evidence-basis to support such practice. In fact, in a study carried out with normal pre-foaling mares clenbuterol was not effective in delaying parturition, and treated mares foaled earlier than control mares.

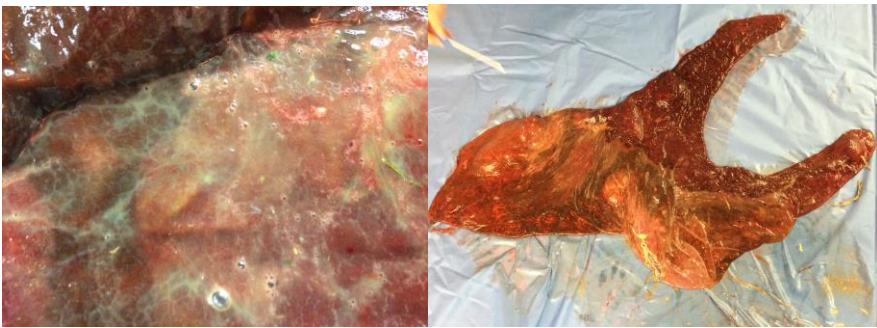
Acknowledgements

These notes are extracted from: Canisso IF, Ball BA, Erol E, Squires EL, Troedsson M. Comprehensive review on equine placentitis. Proceedings AAEP 2015, Las Vegas, NV. (in press).

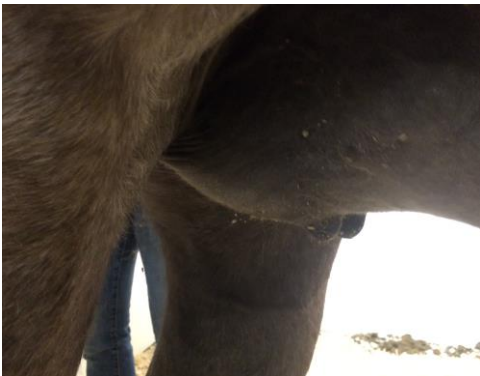Vulvar discharge in a mare with bacterial ascending placentitis



Bacterial placentitis (Chorionic surface)



Premature mammary gland development in a mare with bacterial placentitis



Septic foal born from a mare diagnosed with bacterial placentitis

