Vet Pathol **45**:401–408 (2008)

Feather-picking Psittacines: Histopathology and Species Trends

M. M. Garner, S. L. Clubb, M. A. Mitchell, and L. Brown

Northwest ZooPath, Monroe, WA (MMG); The Rainforest Clinic for Birds & Exotics, Loxahatchee, FL (SLC); Louisiana State University, Department of Veterinary Clinical Sciences, School of Veterinary Medicine, Baton Rouge, LA (MAM); Histology Consulting Service, Everson, WA (LB)

Abstract. Histologic findings are described for 408 feather-picking or self-mutilating psittacines with the use of biopsies from clinically affected and unaffected skin. Inflammatory skin disease was diagnosed in 210 birds, and traumatic skin disease was diagnosed in 198 birds. Criteria used for the diagnosis of inflammatory skin disease included the presence of perivascular inflammation in the superficial or deep dermis of clinically affected and unaffected sites. The primary histologic criteria for the diagnosis of traumatic skin disease were superficial dermal scarring with or without inflammation in the affected sites and an absence of inflammation in the unaffected sites. The inflammatory cells associated with the lesions were typically lymphocytes and occasionally plasma cells, histiocytes, and granulocytes. A preponderance of inflammatory skin disease was seen in macaws (*Ara* spp.) and Amazon parrots (*Amazona* spp.). A preponderance of traumatic skin disease was seen in cockatoos (*Cacatua* spp.) and African grey parrots (*Psittacus erithacus*). The prevalence of each was approximately equal in several other species, including conures (*Aratinga* and *Pyrrhura* spp.), eclectus parrots (*Eclectus roratus*), quaker parrots (*Myiopsitta monachus*), cockatiels (*Nymphicus hollandicus*), parakeets (*Cyanorhamphus* and *Psittacula* spp.), and caiques (*Pionites* spp.). No geographic or gender-based trends were identified. These findings could be helpful for identifying and treating birds with feather-picking disorders.

Key words: Dermatitis; feather picking; histopathology; parrot; psittacine; self-mutilation.

Diseases of the skin constitute a large proportion of case submissions to veterinary diagnostic laboratories, and many distinct entities have been well characterized, especially in domestic mammals. Patterns of histologic change reliably identify specific entities and pathogenic events, such as hypersensitivity dermatitis, vasculitis, and autoimmune skin disease.[4] Pattern-based histologic interpretation of skin disease is not documented in birds, although extrapolation from the mammalian literature might be applicable to some avian cutaneous lesions, such as follicular dysplasia, vasculitis, and hypersensitivity.[3] Intradermal allergy testing has been attempted in psittacines but with ambiguous results.[7] As with mammalian skin disorders, skin biopsy appears to provide useful diagnostic information for avian skin disorders.[1–3,11,12]

Feather loss or destructive behavior and self-mutilation of the skin are common problems in captive birds, particularly psittacines.[1–3,11,12] A number of causes have been identified or suggested, including mycotic, bacterial, viral, and parasitic agents; hypersensitivity; hormonal derangements; hepatic or pancreatic disease; and psychogenic disorders.[1–3,5,8,10–12] Pathologists working with skin biopsies from feather-picking birds have recognized histologic patterns in affected skin that suggest an inflammatory basis for this behavior in some birds, whereas other birds have lesions attributed only to self-induced trauma.[1–3,11] Remarkably, at least 1 report suggests that inflammation is not a contributing factor for feather picking in psittacines.[10] Our study summarizes histologic findings of a retrospective study of paired biopsies from birds with feather loss, feather picking, or self-mutilating behavior and determines the presence or absence of inflammation not attributed to trauma in these birds.

Materials and Methods

Animals

A retrospective study of avian skin disease was conducted from cases submitted to Northwest ZooPath during the years 1994–2005. All cases diagnosed or coded with dermatitis, skin trauma, inflammatory skin disease, psychogenic disorder, self-mutilation, or feather picking were reviewed. From this group, all cases that had sample collection compliant with a paired biopsy protocol[1] received further consideration, whereas remaining cases were excluded from the study. Any cases that had histologically recognizable infectious agents, neoplasia, or follicular dysplasia also were excluded from this study.

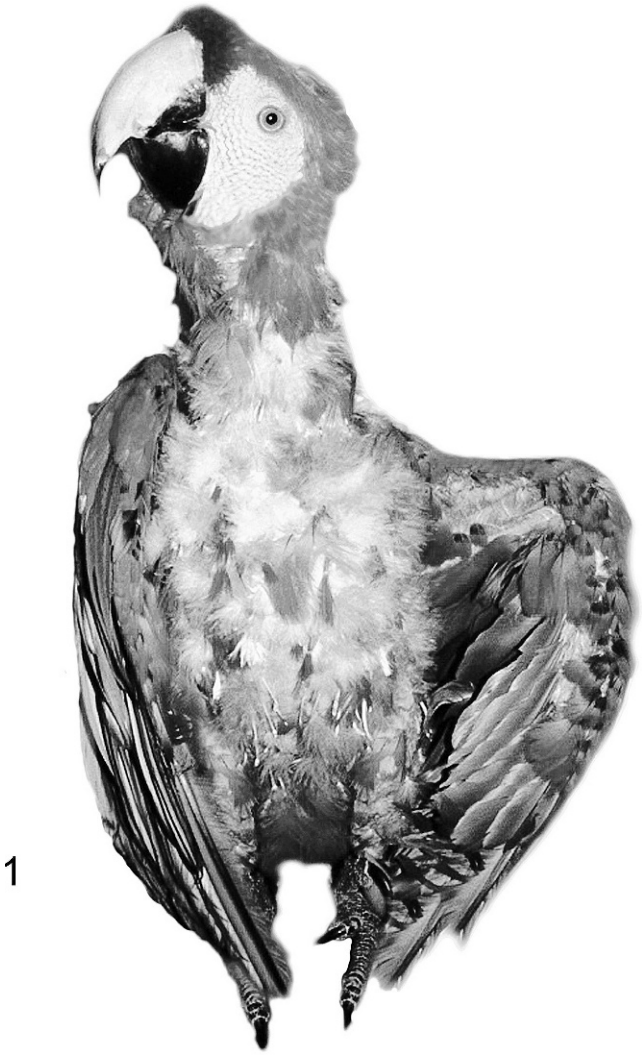

Fig. 1. Inflammatory skin disease; scarlet macaw (*Ara macao*). Note loss of contour feathers over the chest, ventral aspects of the neck, left leg, and over the patagium. These areas are easily reached by the beak and feet.

Fig. 2. Skin; African grey parrot. Note feather tracts with emerging blood feathers (arrow), and empty follicular ostia where feathers have been pulled by the bird but new blood feathers have not yet emerged (arrowhead). Wedge biopsies should include feather follicles that contain blood feathers and surrounding skin.

Biopsy technique

Biopsies were obtained from affected and unaffected sites of birds that had evidence of feather picking, feather loss, or dermatitis (Fig. 1). The paired biopsy protocol requested that clearly labeled full-thickness wedge biopsies of skin and feather be obtained from affected and unaffected sites on the same bird and fixed routinely in formalin for histologic examination. Sites were to include a blood feather and or feather tract if possible (Fig. 2). Affected sites were clinically abnormal and usually were areas easily reached by the bird's beak such as the legs or chest. Unaffected sites were areas that appeared clinically normal or were not easily reached by the bird, such as the top of the head or back of the neck.

Good sectioning of feathered skin requires much practice, and the technique is described in detail herein: Normal and abnormal samples were processed identically, except that the normal samples were inked black (Cancer Diagnostics, Inc. Catalog No. 0728-1, Cancer Diagnostics, Inc., PO Box 1205 Birmingham, MI 48021) with a cotton tip swab and allowed to dry for 3 minutes before proceeding with trimming. The samples underwent routine overnight processing and were embedded in type 9 paraffin (Catalog No. 8337, Richard Allan Scientific, 225 Parsons Street, Kalamazoo, MI 49007). After cooling the paraffin sample block and facing into the block, the sample was returned to the wet ice tray for 5–10 minutes. An initial section was then cut at 4 μm and laid out onto a 43°C distilled water tissue float bath. Then after again facing into the block approximately 60–100 μm, depending on the size of the feather sample, the sample block was allowed to soften on a wet ice tray for 5–10 minutes before sectioning. This process was repeated for a total of 3 levels. The slides were placed into a slide dryer oven at 75°C. for 30 minutes. The slides were then stained routinely with hematoxylin and eosin (HE).

Histologic criteria

A histologic section of normal skin and follicle with blood feather is illustrated in Fig. 3. The primary histologic criteria for the diagnosis of traumatic skin disease were superficial dermal scarring in the affected sites (Fig. 4) and a general absence of inflammation in the unaffected sites. Additional lesions attributed to beak or foot trauma included feather crush, stripping of the shaft and barbules (Fig. 5), and retroflexion of the barbules because of adhesions to the inner follicular sheath at the level of the infundibulum (Figs. 6, 7). Affected sites sometimes also had varying degrees of

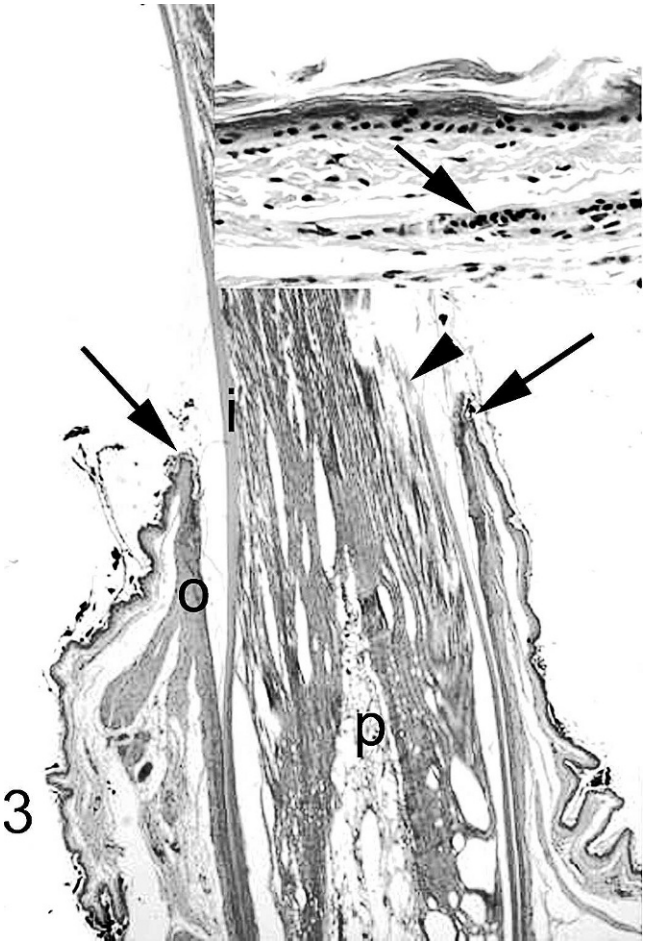

Fig. 3. Normal skin and blood feather; Blue and gold macaw (*Ara ararauna*). Note inner (i) and outer (o) follicular sheaths, pulp cavity (p), infundibulum (arrows), and emerging barbules (arrowhead). *Inset:* Higher magnification of skin adjacent to a follicle, showing 1–2-cell thickness of normal epidermis, dermal collagen fibers, and a small blood vessel in the superficial dermis (arrow). HE.

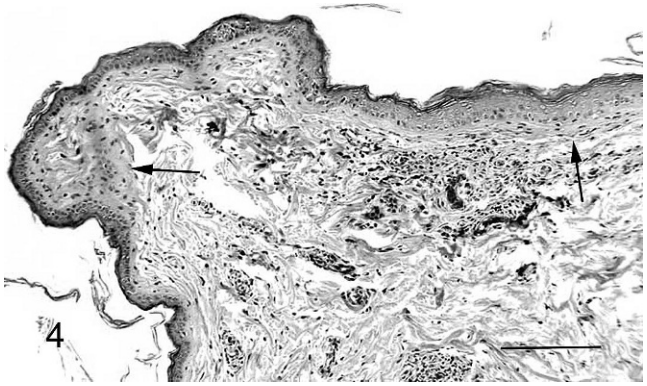

Fig. 4. Traumatic dermatitis; Mollucan cockatoo (*Cacatua moluccensis*). Note increased thickness of epidermis and mild compact hyperkeratosis (compared with Fig. 3), foci of superficial dermal scarring (arrows), and foci of perivascular inflammation. HE. Bar = 200 μm.



Fig. 5. Feather trauma; African grey parrot. Note frayed (arrows) and scalloped (arrowheads) foci on the external surface of the inner follicular sheath from beak trauma incurred while pulling on the shaft. Compare with the external surface of the normal feather sheath in Fig. 7. HE.

epidermal hyperplasia, compact orthokeratotic hyperkeratosis, and perivascular to diffuse inflammation. Inflammation was typically characterized by the presence of lymphocytes, plasma cells, and histiocytes, although eosinophilic granulocytes (heterophils or eosinophils) were occasionally seen, particularly in ulcerated skin lesions. These birds sometimes also had some scarring in the unaffected sites. Rarely, perivascular inflammation was also seen in unaffected sites but was considered disproportionately mild compared with the extent and severity of the dermal scarring.

Criteria used for the diagnosis of inflammatory skin disease included the presence of mild to marked perivascular inflammation in the superficial or deep dermis of clinically affected and unaffected sites (Fig. 8). The inflammatory cells typically associated with the lesions were lymphocytes with fewer plasma cells, histiocytes, and eosinophilic granulocytes. Varying degrees of edema, epidermal and follicular hyperkeratosis, and perivascular pulpitis were also present in some cases. For most cases, it was necessary to examine all 3

Fig. 6. Traumatic dermatitis; cockatoo. An indentation of the inner sheath (arrowhead) and disorganized barbules across the width of the feather (arrows) correspond to a focus of beak crush where the feather emerges from the follicle. The large clear spaces within the feather are artifacts of sectioning. HE.

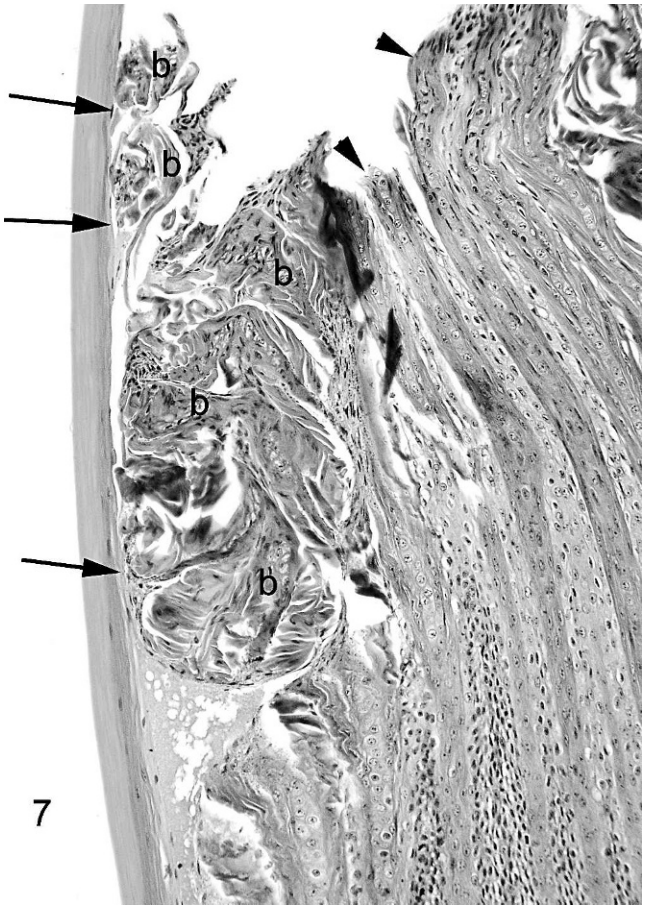

Fig. 7. Higher magnification of feather in Fig. 6; cockatoo. Note retroflexion of the emerging barbules (b) associated with apparent adhesions to the inner surface of the inner sheath (arrows), and attributed to beak-induced feather crush. Adjacent barbules are not affected (arrowheads). The outer surface of the external sheath is normal. HE.

levels of the biopsies to confirm the presence of inflammation, especially in unaffected sites. Cases with histologic evidence of trauma in the unaffected site generally were not included in the inflammatory skin disease group, to avoid confusion regarding the pathogenesis of the inflammation; however, few cases were included in this subset if the scarring was disproportionately mild compared with the severity of the inflammatory process.

Statistical analysis

The 95% binomial confidence intervals (CI) were calculated for each of the proportion estimates. For cases in which the prevalence estimate was 0, the 95% confidence intervals were estimated as previously described.[13] The chi-square test for homogeneity was used to determine whether species, gender, or submission date had an effect on the histopathologic findings. Logistic regression analysis was then used to evaluate the effect of the different independent variables (species, gender, or submission date [time]) simultaneously on outcome (traumatic or inflammatory skin disease). Age could not be included in the model because it was not available. Main effects variables were removed individually from full models to assess the effects on the model likelihood ratio statistics, magnitude of the coefficients for other variables, and Hosmer Lemeshow goodness of fit statistics. Interactions between the main effects variables were also evaluated in the models. SPSS 11.0 (SPSS Inc., Chicago, IL) was used for the analysis. A $P < .05$ was considered statistically significant.

Results

From 1994 to 2005, 16,162 avian biopsies or necropsies were accessioned at Northwest ZooPath. Dermatitis or skin trauma was diagnosed in 1,183 birds (7.3%, 95% confidence interval [CI] 5.8–8.7). With the use of paired biopsy criteria, 408 psittacines were included in the study.

The prevalence of inflammatory skin disease in the sample population was 51.5% (210/408; 95% CI 46.2–55.8), whereas the prevalence of traumatic skin disease was 48.5% (198/408; 95% CI 44.2–53.8). Differences in the type of diagnosis (trau-

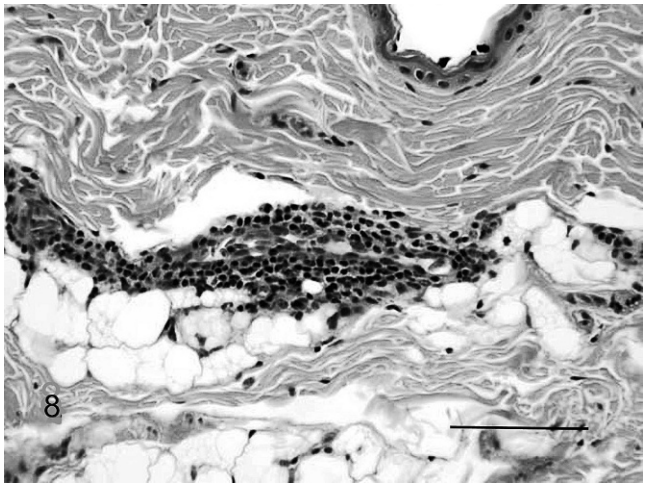

Fig. 8. Inflammatory skin disease; Eclectus parrot (*Eclectus roratus*). Note moderate perivascular inflammatory cell cuff in the superficial dermis, lack of scarring, and normal epidermal thickness. This biopsy was from a clinically unaffected site on the back of the head. HE. Bar = 100 μm.

matic or inflammatory) made for cockatoos (*Cacatua* spp.), African grey parrots (*Psittacus erithacus*), macaws (*Ara* spp.), lorikeets and lories (Subfamily Loriinae), and Amazon parrots (*Amazona* spp.) were significant on the basis of the 95% CI (Table 1). Cockatoos and African grey parrots were significantly more likely to have trauma-induced skin disease, whereas macaws, lorikeets, and amazons were significantly more likely to have inflammatory skin disease (Table 1). Statistically significant differences were not seen for conures (*Aratinga* and *Pyrrhura* spp.), eclectus parrots (*Eclectus roratus*), quaker parrots (*Myiopsitta monachus*), cockatiels (*Nymphicus hollandicus*), parakeets (*Cyanorhamphus* and *Psittacula* spp.), caiques (*Pionites* spp.), lovebirds (*Agapornis* spp.), or parrotlets; for hawk-headed (*Deroptyus accipitrinus*), Senegal (*Poicephalus senegalus*), Jardine (*Poicephalus gulielmi*), or Alexandrine (*Psittacula eupatria*) parrots; or for parrots of unknown genus.

In this study, 115 (28.2%) birds were male, 131 (32.1%) were female, and 162 were of unknown gender (39.7%). There was a significant difference in the diagnoses between female and unknown gender (χ^2 8.7, P = .01) (Table 2). On the basis of the 95% CI, there was also a significant difference in the diagnoses within unknown gender (Table 2).

Skin biopsy samples were received every month and averaged from 5.1% (August) to 15.3% (July). Sample submission was skewed for the month of February (15.3%), however, as a result of a large number of lorikeet samples being submitted from the same collection. There did not appear to be any difference in distribution of inflammatory or traumatic skin disease on the basis of location of the bird within the United States at the time of biopsy.

In the final logistic regression model, only species (χ^2 13.9, P = .0001) was included in the model.

Table 1. Prevalence and 95% CI of traumatic and inflammatory skin lesions observed in psittacines from Northwest ZooPath.

		Traumatic		Inflammatory	
Group	*n*	Percent	95% CI	Percent	95% CI
Cockatoo	98	73.5*	64.7–82.2	26.5*	17.7–35.2
African grey	77	74.0*	64.0–84.0	26.0*	16.0–36.0
Macaw	48	20.8*	9.3–32.3	79.2*	67.7–90.7
Lorikeets	39	0.0*	0–7.6**	100.0*	
Amazon	30	23.3*	8.2–38.4	76.7*	61.6–91.8
Conure	28	46.4	27.9–64.8	53.6	35.1–72.1
Eclectus	22	36.4	16.4–56.4	63.6	43.6–83.6
Quaker	13	46.2	19.1–73.3	53.8	26.7–80.9
Lovebird	11	54.5	25.1–83.9	45.5	16.1–74.9
Cockatiel	11	54.5	25.1–83.9	45.5	16.1–74.9
Parakeet	7	57.2	20.5–93.8	42.8	6.1–79.4
Caique	6	33.3	4.4–71.0	66.7	29.7–100
Hawkshead	4	25.0	0.0–67.4	75.0	32.6–100.0
"Parrot"	4	50.0	1.0–99.0	50.0	1.0–99.0
Senegal	3	33.3	0.0–86.6	66.7	13.4–100.0
Jardine	3	33.3	0.0–86.6	66.7	13.4–100.0
Alexandrine	2	0.0		100	
Parrotlet	2	50		50	

* Significant difference between diagnoses.

Table 2. Prevalence of skin lesions by gender.

Gender	*n*	Traumatic		Inflammatory	
		Percent	95% CI	Percent	95% CI
Male	115	47.8	38.7–56.9	52.2	43.1–61.3
Female	131	58.0**	49.5–66.4	42.0	33.5–50.4
Unknown	162	40.7* **	33.1–48.2	59.3*	51.7–66.8

* Significant difference between diagnoses according to 95% CI.
** Significant difference between gender ($P = .01$).

There were no significant interaction terms. The final model was: traumatic feather disease $= -0.36 + 0.090 \times$ species.

Discussion

A "paired" biopsy protocol was devised to aid in understanding the cause or causes of feather picking or self-mutilation in birds,[1] and this study summarizes data collected with this protocol. Psittacines have ample beaks and claws and are adroit at scratching or chewing most parts of the body, for whatever reason. The top of the head and back of the neck often are the areas that are spared in birds presenting with advanced alopecia or evidence of self-mutilation.[3] Therefore, these areas seem most likely to have the least histologic change attributed to excoriation and were the preferred sites for specimens designated as "unaffected"; also, it seemed logical that parrots with generalized inflammatory skin disease would have inflammatory changes in the sites with less or no excoriative change. The results of this study supported these suppositions, and histologic findings in the unaffected sites were essential for designations of inflammatory or noninflammatory skin disease. In most of the authors' cases it is felt that biopsy of a traumatized site alone would not provide sufficient information for determining the presence of an underlying inflammatory process, because inflammation would be a component of the tissue response to beak or foot trauma.

The cause for traumatic skin disease in these birds was not determined; a number of causes have been proposed, including behavioral problems, hormonal imbalances, infectious agents, follicular dysplasia, and hypersensitivity.[1–3,11,12] The results of this study indicate that a subgroup of traumatic skin disease likely exists that is not associated with underlying inflammatory skin disease, infectious agents or follicular dysplasia. For these birds, a psychogenic abnormality is considered possible, but this could be difficult to prove. Particularly interesting are the trends identified in the study for certain species. A large proportion of the cockatoos and African grey parrots had traumatic skin disease, 2 groups of parrots that are notorious for feather-picking behavior in captivity;[1–3] however, a smaller number of cockatoos and grey parrots also had inflammatory skin disease on the basis of study criteria, so biopsy is considered important to fully characterize the lesions associated with feather picking in these species.

Our findings support previous reports that inflammatory skin disease might be prevalent in feather-picking birds on the basis of examination of paired biopsy specimens.[1,2] Inflammatory skin disease was seen in all parrot species in the study and was the predominant presentation in macaws and Amazon parrots. The etiology for inflammatory skin disease in the study birds was not determined. The pattern and the cellular constituents of the inflammation are most suggestive of cutaneous delayed type hypersensitivity.[4,9]

Hypersensitivity is a type of inflammatory reaction caused by an excessive immunologic response. In birds, acute and delayed type hypersensitivity reactions can be elicited to a variety of antigens, including histamine, ConA, pokeweed mitogen, and bovine albumin. In birds, delayed-type hypersensitivity is caused by cell-mediated immune responses occurring at least 24 hours after antigen contact with sensitized T cells. The inflammatory reaction in the skin of birds with delayed type hypersensitivity appears to be similar to that of mammals and comprises primarily perivascular sensitized T cells, although histiocytes, heterophils, and eosinophils can also be components of the inflammatory reaction.[9] The pattern and cellular constituents of the inflammatory response in the birds of this study were similar to those described for experimentally induced hypersensitivity, especially in those birds that lacked a significant traumatic component to the lesion. In this regard, it is considered probable that the inflammatory reactions seen in the "unaffected" sites could be due, at least in part, to some form of hypersensitivity. These reactions might have been a source of discomfort or pruritus for the birds and

thus could have been a cause of the feather picking or self-mutilation.

Sectioning feathers for optimal histologic examination can be difficult. Our technique, described in detail herein, was refined over several years. It was necessary to examine at least 3 sections in the block for many of the cases, especially in the "unaffected" sites, to detect inflammatory changes, indicating that a thorough microscopic examination is necessary to document the inflammation in some cases. In a detailed report of the normal histology of the avian integument, inflammation is not described.[6] Inflammation for which the cause cannot be identified probably should not be regarded as nonspecific, incidental, or insignificant. In the authors' opinion, the presence of inflammation in the skin of birds is not normal, can be a source of discomfort or pruritus for affected birds, and provides at least one plausible explanation for the feather picking or self-mutilation seen in some psittacines. On the basis of the large number of affected species, obvious species trends, and wide demographic distribution of affected birds, it is considered likely that more than 1 etiologic event might exist. Our findings are in contrast to those of a previously published report that did not associate inflammatory skin disease with feather-picking birds.[10] Although that study had a similar species distribution, sample size was much smaller (8 birds total), and a paired sampling technique with multilevel histologic examination was not used. Future studies similar to those in chickens[9] documenting the phenotype of inflammatory cells in the skin lesions with immunohistochemistry might prove useful in further differentiating these inflammatory and traumatic lesions.

The outcome between females and birds of unknown gender, and between birds of unknown gender was significantly different. This might not be unexpected in that the number of birds of unknown gender was greater than the number of female birds, and it is difficult to ascertain the gender of psittacines without molecular or surgical testing. The fact that there was no difference between known males and females, suggests that a difference between females and unknown genders might disappear if the genders were known. The difference between known genders is likely the result of an overrepresentation of those species found with inflammatory disease (e.g., macaws, lorikeets, and amazons) that had never been sexed.

No seasonal trends were noted for traumatic or inflammatory skin disease; however, these data should be interpreted conservatively regarding seasonal occurrence. Many of the birds had a long history of feather-picking or self-mutilating behavior and the precise onset of the condition might not have been known, or the biopsies might not have been obtained at the precise onset of the condition.

All of the lorikeets in the study had inflammatory skin disease; however, all were from a single captive population. Lorikeets and lories are common pet and exhibit species and are widely distributed in captivity. The study findings suggest that lorikeets could be susceptible to inflammatory skin disease, but that it might not be common in the general captive population. No budgerigars (*Melopsittacus undulatus*) met the criteria for this study, suggesting that this common pet species might not be prone to feather-picking behavior or self-mutilation. Very few nonpsittacine cases fit criteria for inclusion in this study (data not shown), perhaps because fewer dermatopathies are recognized because of less human contact with these birds or because a lower prevalence of inflammatory skin disease exists for nonpsittacine species.

Our findings indicate that inflammatory skin disease and traumatic skin disease occur in feather-picking or self-mutilating birds and appear to be distinct entities and that species trends exist for both presentations. Paired samples from clinically affected and unaffected sites are helpful aids for the pathologist interpreting biopsies from these patients. We emphasize the importance of examining sections at multiple levels in the block to lessen the possibility that inflammatory changes are overlooked.

Acknowledgements

Northwest ZooPath is grateful to the following institutions for submission of study cases: Avicultural Breeding & Research, Loxahatchee, FL; All Creatures Vet Hospital, Stuart, FL; All Creatures Animal Hospital, Bremerton, WA; Angell Animal Medical Center, Boston, MA; Animal Hospital of Centereach, Centereach, NY; Animal Health Clinic, Jupiter, FL; Barberton Vet Clinic, Norton, OH; Bethel Park Animal Hospital, Bethel Park, PA; Bird & Exotic Clinic of Seattle, Seattle, WA; Dallas Zoo, Dallas, TX; Des Moines Vet Hospital, Des Moines, WA; Djurkliniken Roslagstull, Stockholm, Sweden; Ellensburg Animal Hospital, Ellensburg, WA; Floridawild Vet Hospital, Deland, FL; Fort Worth Zoo, Fort Worth, TX; Guardian Animal Hospital, Ashland, KY; Hendricks County Animal Hospital, Danville, IN; Dr. Jackie Gai, Vacaville, CA; Kansas State University, Manhattan, KS; Karlskrona Distr. Vet Station, Lyckeby, Sweden; Kraft Mobile Vet Services, Snohomish, WA; Los Angeles Zoo, Los Angeles, CA; Latah Creek Animal Hospital, Camano Island, WA; Old County Animal Clinic, Plainview, NY; Dr. Susan Clubb, Loxahatchee, FL; Regiondjursjukhuset Helsingborg, Helsingborg, Sweden; Safari Animal Care Center,

League City, TX; Sno-Wood Vet Hospital, Snohomish, WA; Summertree Animal & Bird Clinic, Dallas, TX; The Toledo Zoo, Toledo, OH; Valley Animal Hospital, Roanoke, VA; Village Vet Hospital, Bellingham, WA; West Valley Pet Clinic, Woodland Hills, CA; Windcrest Animal Hospital, Wilmington, DE; and Yukon Vet Hospital, Yukon, OK. The authors also thank Jamie Kinion for data retrieval and Christie Buie for photo editing, illustration layout, and manuscript submission.

References

1 Clubb SL, Garner MM, Cray C: Detection of inflammatory skin disease in psittacine birds using paired skin biopsies, Proc Assoc Avian Vet, Monterey, CA, pp. 193–199, 2002.

2 Clubb SL, Garner MM, Cray C, Arheart K, Goodman M: Diagnostic assessment of feather damaging behavior in African grey parrots (*Psittacus erithacus*), Proc Assoc Avian Vet, New Orleans, LA, pp. 313–320, 2004.

3 Garner MM: Avian noninfectious skin disorders, Proc Assoc Avian Vet, Pittsburgh, PA, pp. 21–23, 2003.

4 Gross TL, Ihrke PJ, Walder EJ, Affolter VK: Diseases of the dermis. *In:* Skin Diseases of the Dog and Cat, Clinical and Histopathological Diagnosis, ed. Gross TL, Ihrke PJ, Walder EJ, and Affolter VK, 2nd ed., pp. 199–399. Blackwell Science, Ames, IA, 2005

5 Lothrop CD: Thyrotropin stimulation test for evaluation of thyroid function in psittacine birds. J Am Vet Med Assoc **186:**47–48, 1985

6 Lucas AM, Stettenheim PR: Avian anatomy. Integument. Agricultural handbook 362, pp. 485–635. US Department of Agriculture, Washington, DC, 1972

7 Nett CS, Hosgood G, Heatley JJ, Foil CS, Tully TN: Evaluation of intravenous flourescein in intradermal allergy testing in psittacines. Vet Dermatol **14:**323–332, 2003

8 Oglesbee BL: Hypothyroidism in a scarlet macaw. J Am Vet Med Assoc **201:**1599–1601, 1992

9 Parmentier HK, De Vries Reilingh G, Nieuwland MGB: Kinetic and immunohistochemical characteristics of mitogen-induced cutaneous hypersensitivity in chickens selected for antibody responsiveness. Vet Immunol Immunopathol **66:**367–376, 2003

10 Rosenthal KL, Morris DO, Maudlin EA, Ivey ES, Peikes H: Cytologic, histologic and microbiologic characterization of the feather pulp and follicles of feather-picking psittacines birds: a preliminary study. J Avian Med Surg **18:**137–143, 2004

11 Schmidt R: Use of biopsies in the differential diagnosis of feather picking and avian skin disease, Proc Assoc Avian Vet, Nashville, TN, pp. 113–118, 1993.

12 Schmidt RE, Lightfoot TL: 2006. Integument. *In:* Clinical Avian Medicine, ed. Harrison GJ and Lightfoot TL, vol. 1, pp. 395–410. Spix Publishing, Palm Beach, FL, 2006

13 Van Belle G, Millard SP: STRUTS: Statistical Rules of Thumb©, pp. 3–14. Departments of Environmental Health and Biostatistics, University of Washington, Seattle, WA, 1998

Request reprints from Dr. Michael M. Garner, Northwest ZooPath, 654 West Main, Monroe, WA 98296 (USA). E-mail: zoopath@aol.com.